

An implant that does not smell

Implant, który nie sprzyja halitosis

The Royal College of Surgeons, London, UK

Abstract

In modern implantology the implant systems should offer a tissue care concept to satisfy the patient needs. The demand for long-term aesthetic results is a request from patients and dentists. Bone loss and abutment loosening need to be avoided and are the result of weak implant abutment connections. The subcrestal implant placement will become more and more important in the future to keep the bone and in the same moment the soft tissue.

Key words: conical taper, implant abutment connection, abutment loosening, loss of bone, aesthetics.

Streszczenie

W nowoczesnej implantologii systemy implantologiczne powinny oferować ochronę tkanek, aby zaspokajać potrzeby pacjentów. Wymóg długoterminowej estetyki jest stawiany zarówno przez pacjentów, jak i przez lekarzy dentystów. Utrata kości i poluznienie implantu, których należy unikać, są rezultatem słabego połączenia implant-filar. Umieszczenie implantu subkrestalnie będzie w przyszłości coraz bardziej znaczące dla zachowania kości i tkanek miękkich.

Słowa kluczowe: połączenie stożkowe, połączenie implant-filar, poluznienie filaru, utrata kości, estetyka.

Have you ever noticed that whenever you detach an abutment from an implant everybody in the room knows about it? There is a distinct odour that emanates from the space between the abutment and the implant. This is inevitable because of the dead space that exists between an implant and the abutment. There is always leakage into this dead space and consequently stagnation with the inevitable proliferation of micro-organisms and their toxic by-products. It is no wonder that the activity of disengaging an abutment from the implant is characterized by this distinct and unpleasant olfactory experience for the patient, members of staff and the surgeon.

There are of course other consequences of this beyond that of the unpleasant olfactory experience. The microbial leakage can also be associated with the presence of fistulas in the soft tissues tracking back to the implant-abutment junction [1]. These relate to the constant exudate of microbes and the toxins into the peri-implant space [2, 3]. It has been demonstrated that the amount of bacteria within the sulcus is ten times greater around certain implant systems than the control teeth [4]. There is also the concept of the biological width of approximately 3 mm, which determines the distance between gingival margin and bone level. Bacterial leakage from a micro-gap between abutment and implant has been associated with a loss of bone (or so called remodelling!) around the peri-implant region due to inflammation [3, 5]. And so one may ask oneself,

when the bone goes what happens to the soft tissues, and what happens to the Aesthetics?

In a paper recently published a comparison was made of the leakage between the abutments and implants of five different systems. This was to examine the flow of dyes through the junction between the abutment and the implant. All of the five systems that were tested showed that there was leakage of the dye to varying degrees [6]. And this therefore meant a potential for bacterial proliferation. In a completely separate study published in 1992 by Maiguenther [7], the Ankylos implant system was found to be tight enough, because of its precision, to be able to hold a vacuum for the test period of 60 hours. The precise fit between the abutment and the implant was no doubt as a result of the experience that the company has in manufacturing precision attachments.

The nature of the connection between the implant the abutment is a conical taper (Morse taper). This means that when 2 perfectly co-centric cones are brought together an extremely tight junction is created.

This attachment thus created is considered to be the best joint in the engineering world. Many parts of our automobiles (for example clutch plates and wheel bearings) and aeroplanes (such as engines and wings) where the integrity of the joint is critical depend upon this principle in order to mate two separate components.

The Ankylos conical connection serves several purposes. In addition to forming bacteria proof




Figure 1. Photomicrograph showing the seal that is created between the abutment and the implant with a conical connection.

Rycina 1. Zdjęcie pokazuje stożkowe uszczelnienie powstałe między filarem i wszczepem.

and vacuum tight joint, it provides excellent anti-rotation and stability [8]. Because this junction is not limited by external or internal hex to provide the anti-rotation, the abutment can be connected in any position, which enables it to be orientated to the best prosthetic advantage. Needless to say of course, that the abutment and implant connection now no longer depends upon the strength of screw but is achieved by a the direct frictional lock between the implant and the abutment. It is no wonder, therefore, that the incidence of abutment loosening is reduced considerably from up to 48% to less than 6% [1, 9–15].

But what does this mean in practical terms

1. It means that the implant system has the best of both worlds. The implant can be used either as a submerged or a Trans-mucosal implant. This is essentially because the 2 components become one – without the micro-gap – as soon as the connection between the implant and abutment has been made.

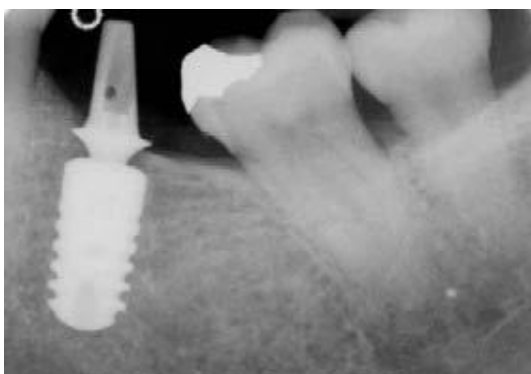


Figure 2. Implant placement into a healed site for immediate loading. Notice the bone levels.

Rycina 2. Umieszczenie implantu w miejscu zagojonym dla natychmiastowego obciążenia.

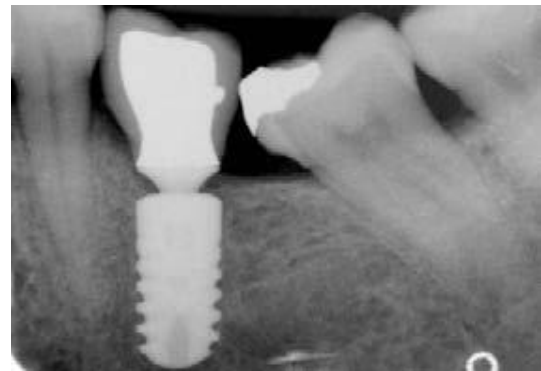

Figure 3. 6 months following the restoration of the implant. The radiograph shows the bone level of the implant.

Rycina 3. 6 miesięcy po odbudowie. Zdjęcie pokazuje poziom kości przy implantacie.

2. Ankylos can be placed to just below the level of the bone and be allowed to heal and loaded when integration has taken place, or the implant can be loaded immediately. The position of the implant below the crest of the bone does not cause any significant bone loss.
3. The selection of the abutment can be done at first stage surgery without any concern for the position of the hex. The abutment connection at second stage surgery (or at first stage surgery for immediate loading) can be carried out with the precise rotational position of the abutment being determined to prosthetic needs. Most importantly any changes that need be made to the rotational position of the abutment can be carried out at any stage [16, 17, 18].
4. Second stage surgery can very effectively be carried out via a tiny incision, which does not

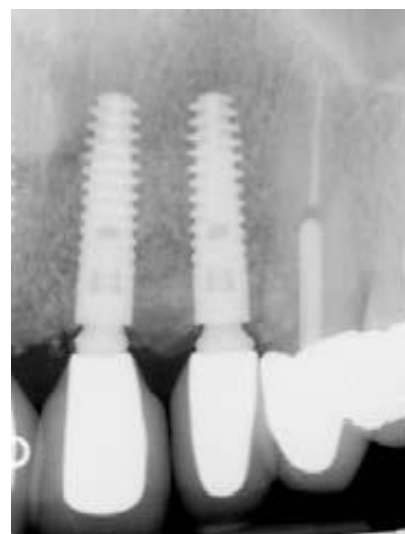


Figure 4. Postoperative radiograph showing multiple implants. This is key to good aesthetic outcome.

Rycina 4. Zdjęcie pozabiegowe wielokrotnej implantacji. Klucz do korzystnych wyników leczenia.

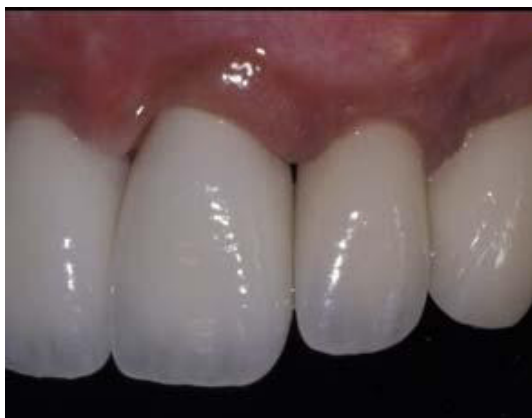

Figure 5. Two implants, adjacent to each other, showing good papilla reform. The maintenance of the level of bone is critical to the sustenance of the papilla.

Rycina 5. Dobrze uformowana brodawka międzyzębowa przy dwóch koronach na implantach. Zachowanie poziomu kości jest bardzo istotne dla podtrzymania brodawki.

require the exposure of the entire implant surface thus leaving the peri-implant bone intact. This is because the implant abutment connection is not made at the outer edge and on top of the implant but internally within the implant. Access is therefore only required to the central portion of the implant.

5. Connection of the abutment to the implant is very simple and safe. The abutment is attached to the implant by positioning the abutment in the correct plane, the taper is engaged by applying finger pressure, and the pre inserted abutment screw is tightened securing the abutment to the implant using only 15 Newton centimetres.
6. The stability of the bone, particularly in between the implants, provides support for soft tissue especially the interdental papilla that is key to the aesthetics.

References

- [1] Jemt T., Laney W.R., Harris D. et al.: Osseointegrated implants for single tooth replacement: a 1-year report from a multicenter prospective study. *Int. J. Oral Maxillofac. Implants*, 1991; 6: 29-36.
- [2] Quirynen M., van Steenberghe D.: Bacterial colonization of the internal part of two-stage implants. An in vivo study. *Clin. Oral Implants Res.*, 1993; 4: 158-161.
- [3] Ericsson I., Persson L.G., Berglundh T., Marinello C.P., Lindhe J., Klinge B.: Different types of inflammatory reactions in peri-implant soft tissues. *J. Clin. Periodontol.*, 1995; 22: 255-261.
- [4] Jemt T., Lekholm U., Grondahl K.: 3-year followup study of early single implant restorations ad modum Branemark. *Int. J. Periodontics. Restorative. Dent.*, 1990; 10: 340-349.
- [5] Adell R., Lekholm U., Roskler B.J., Branemark P.I.: A 15-year Study of Osseointegrated Implants in the Treatment of the Edentulous Jaw. *Int. J. Oral Surg.*, 1981; 10: 387-416.
- [6] Gross M., Abramovich I., Weiss E.I.: Microleakage at the abutment-implant interface of osseointegrated implants: a comparative study. *Int. J. Oral Maxillofac. Implants*, 1999; 14: 94-100.
- [7] Mairgünther R., Nentwig G.H.: Das Dichtigkeitsverhalten des Verbindungssystems beim zweiphasigen Ankylos-Implantat (The tightness behavior of the connection system of the 2-phase Ankylos implant). *Z. Zahnärztl. Implantol.*, 1992; V: 50-53.
- [8] Mollersten L., Lockowandt P., Linden L.A.: Comparison of strength and failure mode of seven implant systems: an in vitro test. *J. Prosthet. Dent.*, 1997; 78: 582-591.
- [9] Binon P.P.: Implants and components: entering the new millennium. *Int. J. Oral Maxillofac. Implants*, 2000; 15: 76-94.
- [10] Becker W., Becker B.E.: Replacement of maxillary and mandibular molars with single endosseous implant restorations: a retrospective study. *J. Prosthet. Dent.*, 1995; 74: 51-55.
- [11] Henry P.J., Laney W.R., Jemt T. et al.: Osseointegrated implants for single-tooth replacement: a prospective 5-year multicenter study. *Int. J. Oral Maxillofac. Implants*, 1996; 11: 450-455.
- [12] Laney W.R., Jemt T., Harris D. et al.: Osseointegrated implants for single-tooth replacement: progress report from a multicenter prospective study after 3 years. *Int. J. Oral Maxillofac. Implants*, 1994; 9: 49-54.
- [13] Levine R.A., Clem D.S. III, Wilson T.G. Jr., Higginbottom F., Solnit G.: Multicenter retrospective analysis of the ITI implant system used for single-tooth replacements: results of loading for 2 or more years. *Int. J. Oral Maxillofac. Implants*, 1999; 14: 516-520.
- [14] Levine R.A., Clem D.S. III, Wilson T.G. Jr., Higginbottom F., Saunders S.L.: A multicenter retrospective analysis of the ITI implant system used for single-tooth replacements: preliminary results at 6 or more months of loading. *Int. J. Oral Maxillofac. Implants*, 1997; 12: 237-242.
- [15] Romanos G.E., Nentwig G.H.: Single molar replacement with a progressive thread design implant system: a retrospective clinical report. *Int. J. Oral Maxillofac. Implants*, 2000; 15: 831-836.
- [16] Sethi A., Sochor P.: Predicting esthetics in implant dentistry using multiplanar angulation: a technical note. *Int. J. Oral Maxillofac. Implants*, 1995; 10: 485-490.
- [17] Sethi A., Kaus T., Sochor P.: The use of angulated abutments in implant dentistry: five-year clinical results of an ongoing prospective study. *Int. J. Oral Maxillofac. Implants*, 2000; 15: 801-810.
- [18] Sethi A., Kaus T., Sochor P., Axmann-Krcmar D., Chanavaz M.: Evolution of the concept of angulated abutments in implant dentistry: 14-year clinical data. *Implant. Dent.*, 2002; 11: 41-51.

Address correspondence to:
Centre of Implants and Reconstructive Dentistry
33 Harley Street, London W1G 9QT
tel.: +44 2076365676, fax: +44 2074368979